

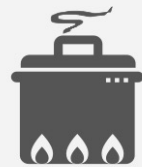# 1 VISION

# ATOMS

## Primary Eye Care


V1 1/22

Diseases are spread by filth & flies  
> *avoid or kill & sanitise*



Dull eyes/measles/underfed?  
> *eat coloured fruit & good bread*

All corneal ulcers can blind  
> *treat urgently to be kind* N5



WHO



WILSON




## Loss of Vision

**GRADUAL** ↓ *months*

**DISTANCE** > *distance glasses*  
cataract, glaucoma, DR, cornea

**NEAR** > *reading glasses*  
+1.5, 2.0, 2.5, 3.0



**SUDDEN** ↓ *days*  
red eye, trauma/chemical,  
cornea, back of eye > *hospital*

blanch, haze, abrasion

**irrigate  
30 mins**

**guide the  
blind**

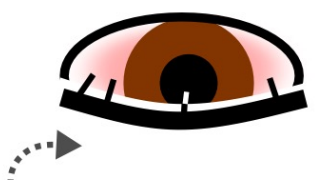
Young	Old	Low Vis	Blind
6/6	6/12	6/18	3/60

## 2 LIDS & LASHES




WATERY (white) eye  
loose lids, tight ducts

**NO RUB+CLEAN**

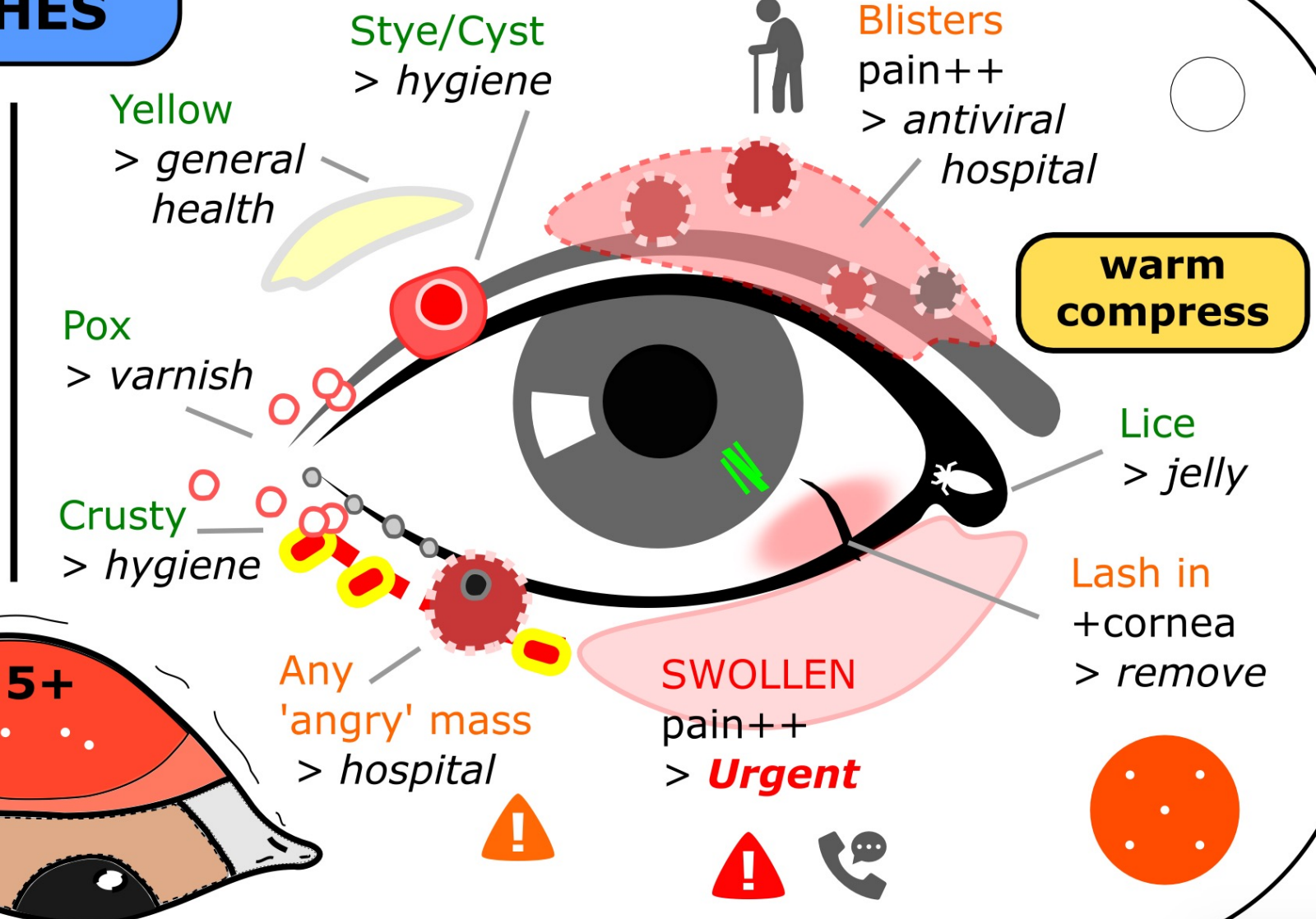
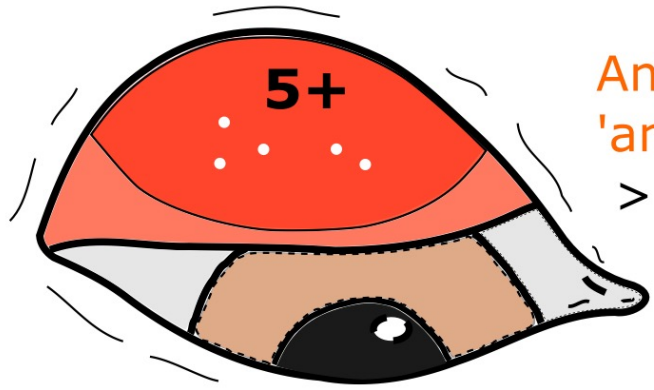


Turn IN

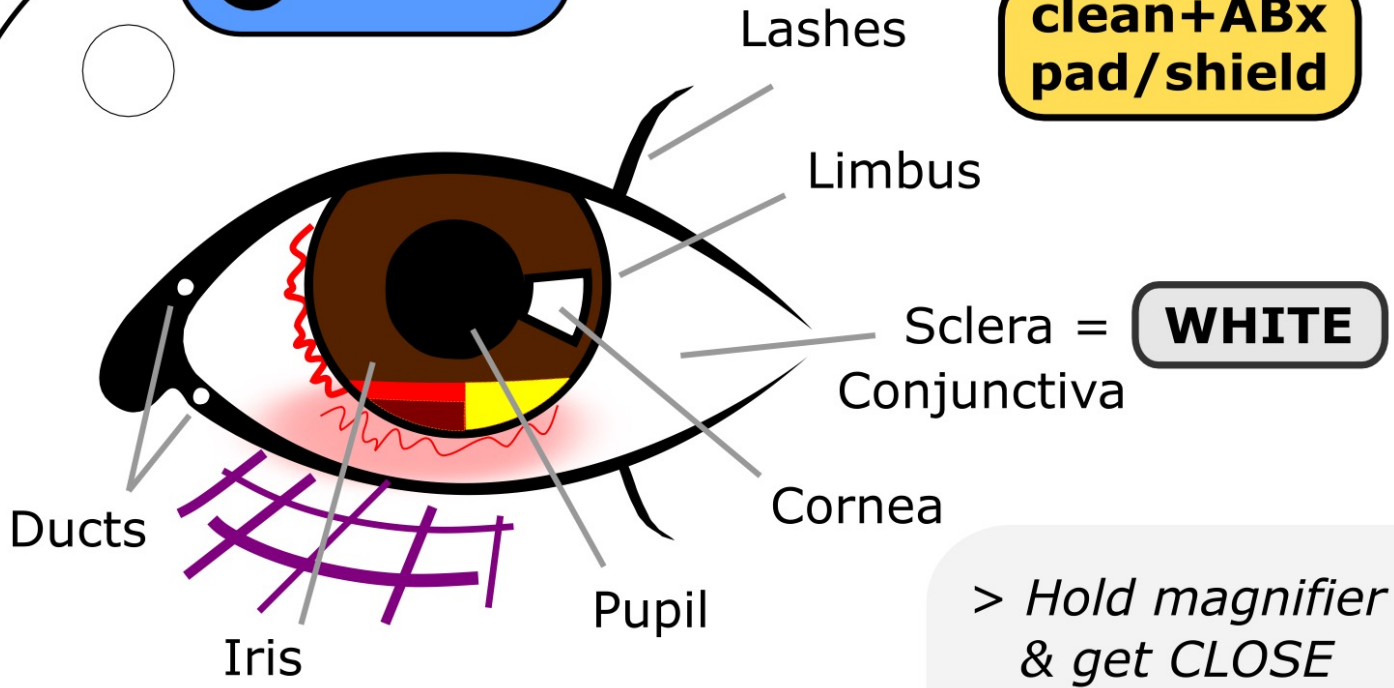


Turn OUT

**TRACHOMA**  
> evert  
0.5mm lumps  
> ABx



### 3 EYE



### RED Eyes

**Baby**  
swollen+  
pus


STD  
↓

> CLEAN  
ABx  
Fever  
> ABx tablets

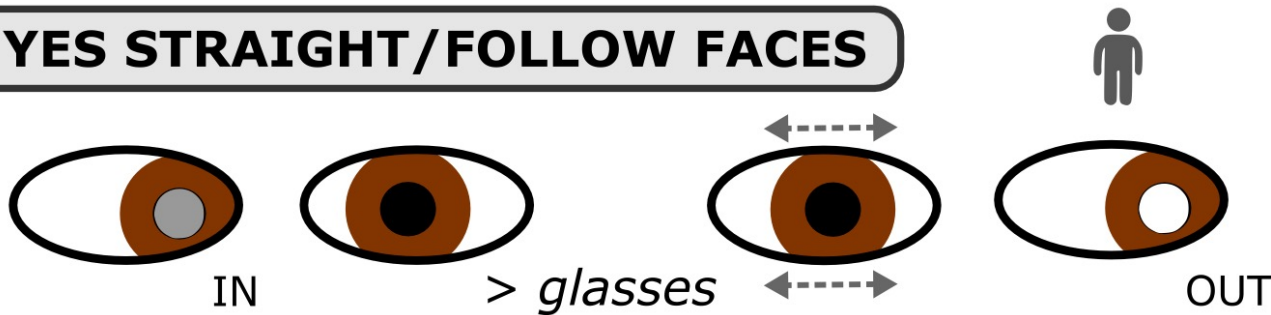
**3mth+**  
itchy/  
watery

↓

> CLEAN  
ABx/allergy  
same 3day  
> hospital

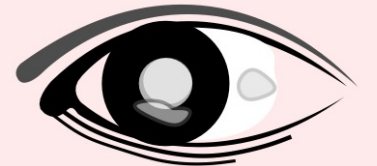

### EYES STRAIGHT/FOLLOW FACES



### DULL Eyes

ANY odd look



Xero, measles, diarrhoea

> Vit A+good food

# 4 CORNEA


CLEAR+WET

instil drops + ointment

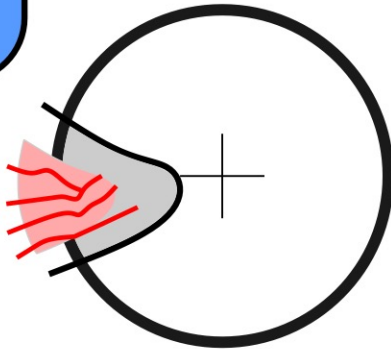
> NaFl



debris




pterygium



arcus



old scar



abrasion

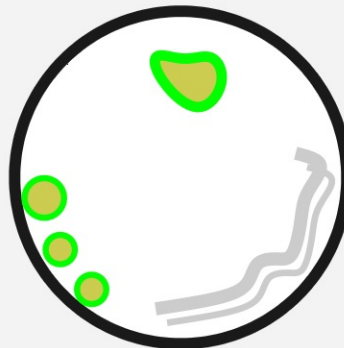
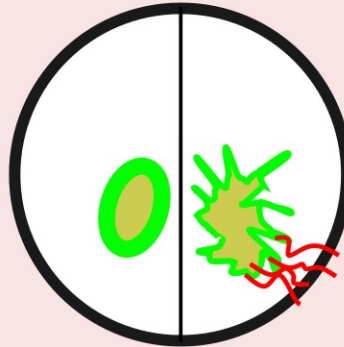
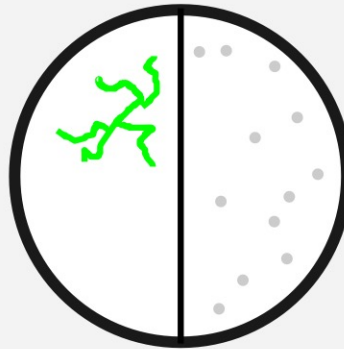
## STAIN+IDENTIFY

BRANCH/DOTS  
> *antiviral, hospital*

ROUND pain+++  
> *ABx*

JAGGED swollen  
> *antifungal*

EDGE or TOP  
> *hospital*



# 5 PUPIL

EQUAL

R <> L



NO reaction  
> hospital  
child Urgent




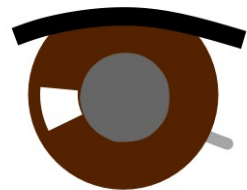
Sleep/Eat  
Move/Think  
Sun WELL



REACTS

BLACK

ROUND



CATARACT/RB  
poor vision  
> hospital



GLAUCOMA  
oval, pain+++  
> Urgent



## Fundal Reflex



know the glow



Normal  
orange-red  
to blue-white



RB  
BV+patchy  
yellow/white




Cataract  
dark



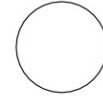
3/3

dog the top 81940 471776 N8

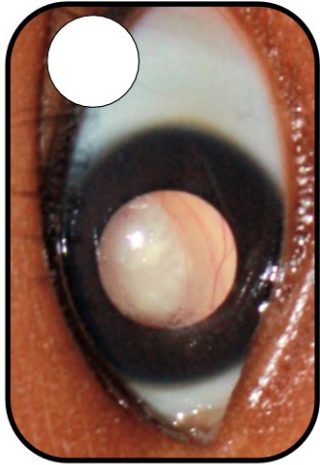
and moon bird 2031 141066 N5



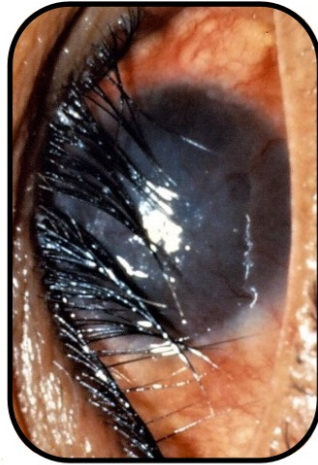3/6



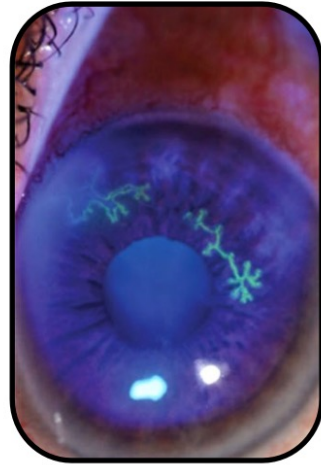3/30



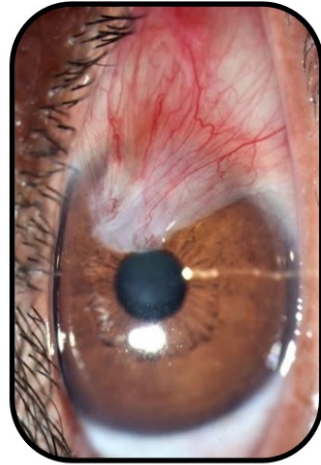
2



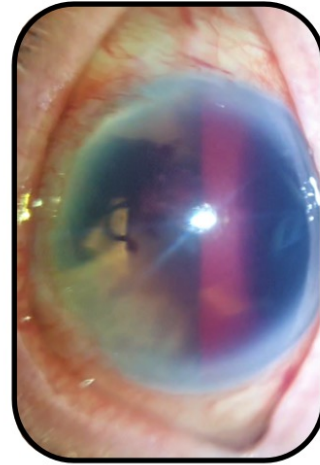
4



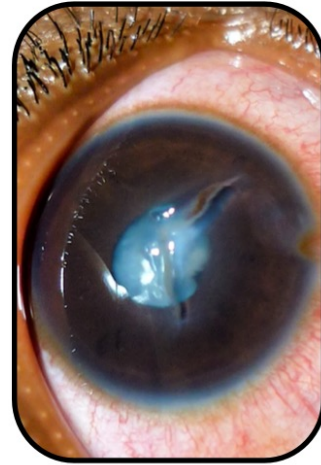
6



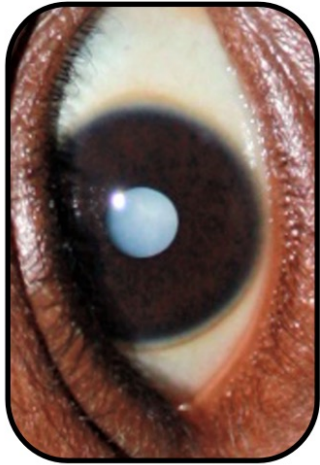8



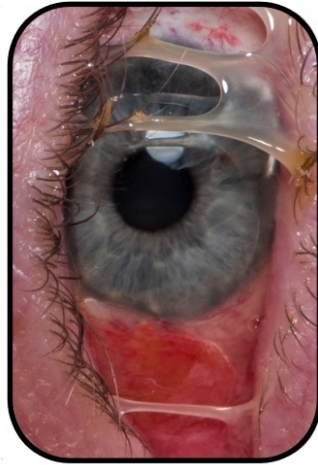
10



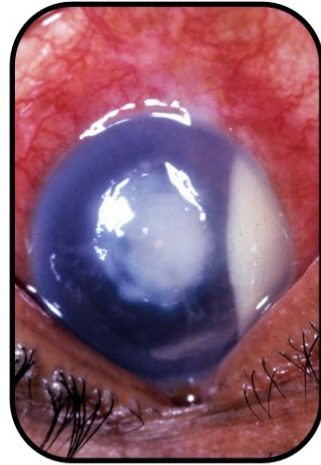12



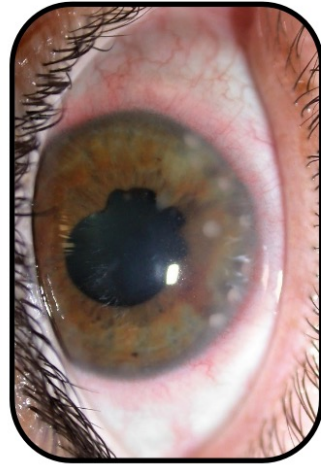
1



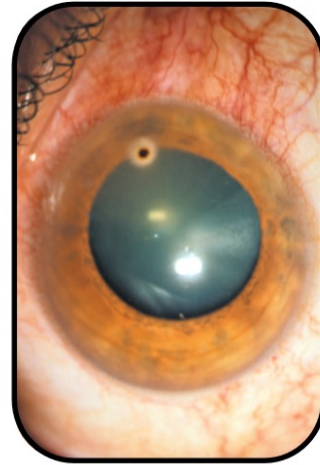
3



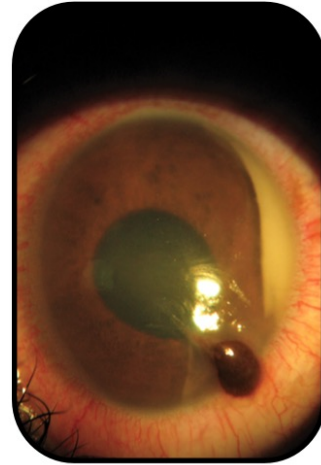
5



7



9




11


## Fundal Reflex



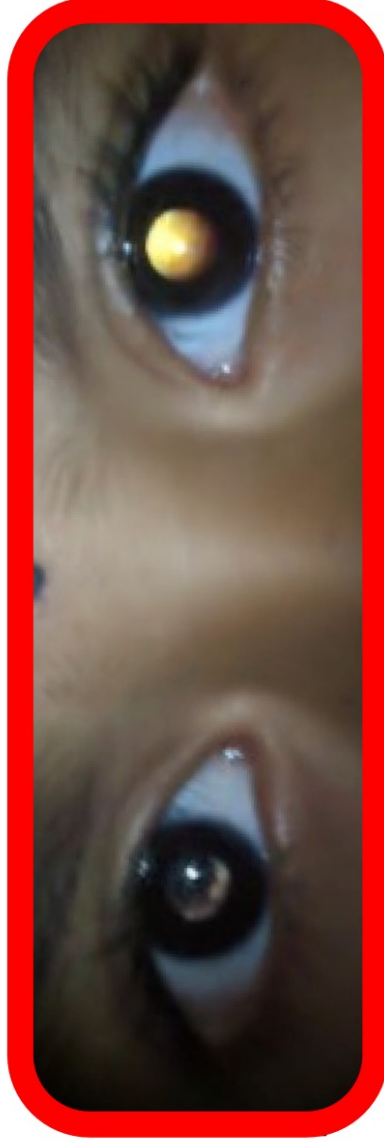
Normal



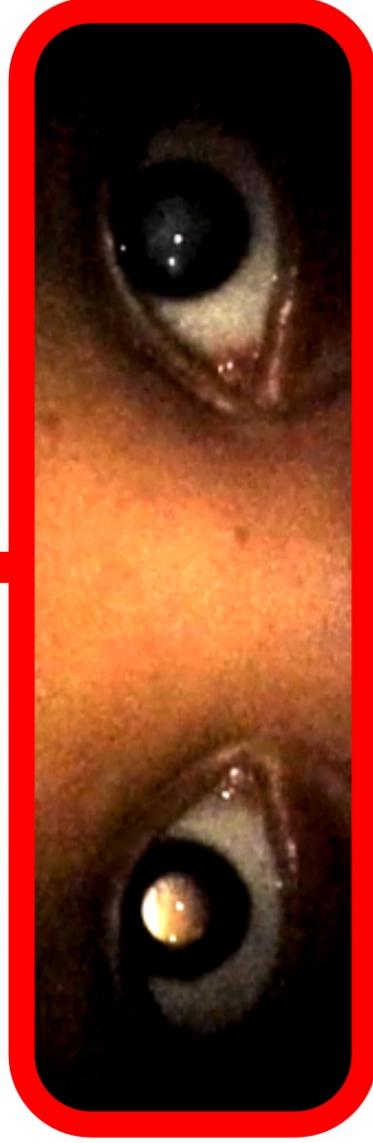
Colour/Brightness difference



Dark patch



No reflex



> dim room+arms-length compare eyes  
**brightness, colour, shape, reflections**  
birth, 6wk, routine visits, any concerns

