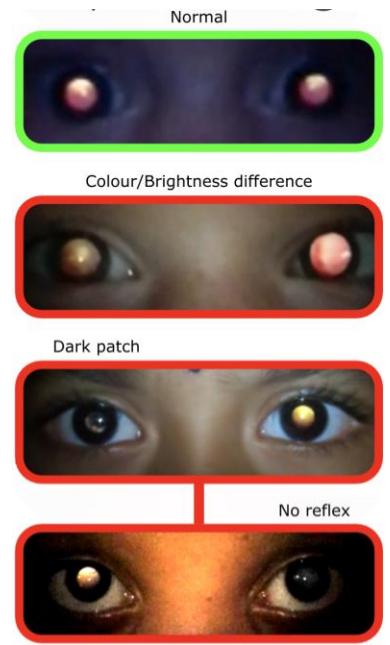



Fundal Reflex



Abnormal fundal reflex

- Cataract
- Retinoblastoma
- Corneal scar
- Squint
- Refractive error
- Structural abnormality



Pupils

